Mechanisms of Injury in Childhood

Jim Anderst, MD, MSCI
Division of Child Abuse and Neglect
UMKC School of Medicine
Children's Mercy Hospital
Kansas City, MO

Disclosure

- This program was created with a grant from the Children's Justice Act of Texas

Objectives

- For head injuries, fractures, and abdominal injuries in children:

1) Review the relevant anatomy
2) Review common injuries (inflicted/accidental)
3) Review the forensic implications
4) Introduce a tool that you can use to improve investigation of severe child physical abuse

Case example

- You are called to investigate a fracture in a 9 month old. You find out from the hospital that the child reportedly fell and broke his right leg.
- What questions do you need to ask the caregivers?
- What questions do you need to ask the medical providers?

Case Example

- The hospital social worker reads the radiology report to you. It states, “Distal buckle fracture of the femoral metaphysis”
- What is that?
- How could that happen?
- It is 2 am, and no medical provider is available to meet with you in the Emergency Room

Case Example

- Without more information from the medical providers, how do you know what to ask the caregivers/potential abusers?

Mechanisms of Injury In Childhood

- Mechanisms of Injury in Childhood is a tool that will be available to you to help you:

1) Better understand the anatomy of the injury
2) Better understand the possible mechanisms of injury (accidental and inflicted)
3) Improve interrogations/interviews

Mechanisms of Injury in Childhood

- Developed with a Children's Justice Act Grant
- Goal of the program is to improve investigation and prosecution of serious physical abuse

Mechanisms of Injury in Childhood

Mechanisms of Injury in Childhood

- Scene investigation and ongoing collaboration between medical and law enforcement/CPS is critical
- Changes in child outcomes/prosecution result from appropriate collaboration

Anderst, et al. 2009

MIC intro

Case Example

- "Distal femoral buckle fracture of the metaphysis"
- You interview the parents
- They tell you the child fell out of bed last night, witnessed only by the father
- Has refused to put weight on the leg since
- This does not seem plausible to you
- The father is taken into police custody and charged with a crime

Buckle Fracture of the Femur

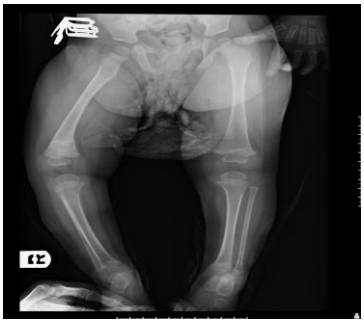

Case Example

- You access MIC

- Buckle fractures
- Buckle fracture of the femur

Case Example

- Based on your further understanding of the injury and mechanisms, you ask additional questions.
- How did the child fall out of bed (feet first/head first?)
- How did the child land, specifically?

Case Example

- The father states that the child fell, feet first
- He landed squarely on his right knee, then tumbled to the ground
- The father's history exactly matches a known accidental mechanism
- You later confer with the medical team, who agrees, based on the information you gathered

Fractures

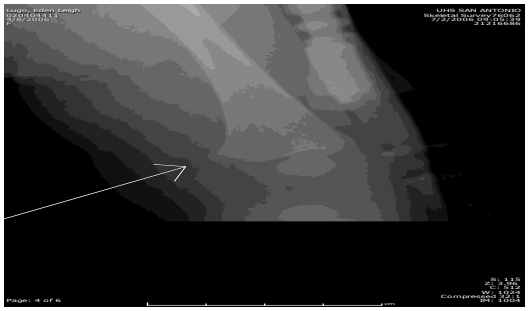

MIC: Fractures Intro

Femur Fracture

- 2 year old presents to the hospital with inability to walk and leg pain
- The father states he didn't see it happen, but that the child was running outside
- Next thing the father saw was the child writhing in pain on the grass
- An x-ray shows a spiral fracture of the femur

Spiral Fracture of Femur

Femur Fracture

- This history is

A) Plausible
B) Unlikely
C) Unable to tell

Spiral Femur Fracture

- You are discussing the case with your co-worker who tells you, “Spiral fractures mean abuse.”
- Is this correct?

- MIC Spiral femur fracture

Spiral Femur Fracture

- You determine, in conjunction with your medical colleagues, that the history is plausible
- The teaching that spiral fractures are indicative of abuse is outdated and incorrect
- Spiral fractures are indicative of twisting
- This may be abusive or accidental

Radius fracture

- An 10 month old is brought to medical care due to swelling of the right wrist
- The mother states she saw the child fall on the wrist while he was standing up holding on to the couch
- X-ray shows the following:

Classic Metaphyseal Fracture of Radius

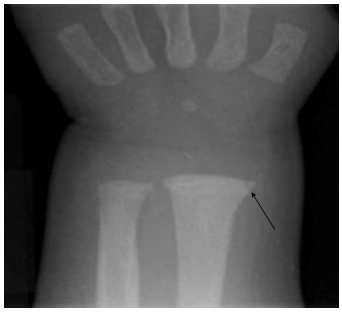

CML of the Radius

- This history is

A)Plausible
B)Unlikely
C)Unable to tell

Why?

MIC: CML of radius

CML of Radius

- You determine that the mother's story is not compatible with the child's injury
- Further questioning reveals that the mother is a victim of DV, and she witnessed the step-father yank and twist the child's arm

Radius fracture

- An 10 month old is brought to medical care due to swelling of the right wrist
- The mother states she saw the child fall on the wrist while he was standing up holding on to the couch
- X-ray shows the following:

Buckle Fracture of Radius and Ulna

Buckle Fracture of the Radius

- The overnight team hands off the case to you.
- They tell you that Law Enforcement has placed mother in jail.

Buckle Fracture of the Radius

- This history is

A)Plausible
B)Unlikely
C)Unable to tell

Why?

MIC: Buckle fracture of the radius

Buckle Fracture of the Radius

- After collaborating with your medical team members, you agree that mom's history matches the injury
- Investigation reveals no other concerns
- Mother is removed from jail and child is returned to her

Clavicle Fracture

- A 10 month old is brought to medical care because he is not using his right arm
- He is quite mobile, actively walking, but often falls
- There is no known specific event that caused the injury
- X-rays show the following:

Clavicle Fracture

Clavicle Fracture

- The ER reports the case to CD
- But, the ER doctor tells you, “this is nothing, we see this all the time”

Clavicle Fracture

- This history, as currently provided,

A)Completely explains the findings
B)Is completely inconsistent with the findings
C)Unable to tell

Why?

MIC: Clavicle Fractures

Clavicle Fracture

- No other significant risks are noted during the investigation
- No one remembers any event that could have caused the injury
- What should you do with this case?
- Don't forget the role of supervisory neglect!!

Clavicle Fracture

- Fracturing the clavicle is painful
- Any coherent caregiver would note that the child was in pain when the event occurred
- Additionally, the child likely would have immediately or nearly immediately stopped using the arm normally

Head Injury

MIC Head Injury Basic Anatomy

Commonly Myths in Head Injury

- Subdural hematoma *means* abuse
- Retinal hemorrhages *mean* abuse
- The last person who was with the child when the child was normal *must have* inflicted the injury
- You can diagnose abusive head injury by looking at the family (it's always mom's boyfriend)

Case Example

- 10 month old came to the ER with altered mental status
- No previous ill symptoms
- A head CT shows the following:

Head CT

- The Head CT shows a “subdural hematoma exerting mass effect on the right hemisphere”

Case continuation

- An opthalmology consult is obtained and shows the following:

Case progression

- Eye exam shows “intraretinal hemorrhages OD, concentrated in posterior pole”
- A skeletal survey is negative
- The child is taken to surgery to have the subdural drained.
- After surgery, the child returns to baseline functioning

Case History

- The only history provided by the family is a fall off of a couch earlier in the day.
- The fall was unwitnessed, but was reportedly heard by the father. Mother was upstairs.
- The child was reportedly found on the ground crying next to an end table and a couch.

Case History

- The child settled, then returned back to normal for several hours.
- The child was then reportedly fussy, then became excessively fussy and started having seizures.
- 911 was then called

Case question

- This child's subdural hematoma and retinal hemorrhages

1) Could have been caused by an accident
2) Must have been caused by violent shaking
3) Are likely the result of a genetic condition
4) None of the above

MIC

- Mass effect subdural hemorrhage
- Retinal hemorrhage

Case question

- In this case the onset of severe symptoms

1) Must have been immediately after the trauma
2) Could have been delayed as reported by the parents
3) None of the above

MIC

- Lucid interval

Case Resolution

- Short falls may occasionally cause subdural hematomas
- Retinal hemorrhages are not diagnostic of abuse and may rarely occur from simple household trauma
- Lucid intervals can happen
- There are specific reasons for lucid intervals that need to be ruled out

Case: Skull Fractures

- A month old is brought to medical care for swelling of the scalp
- His parents relate that he fell off a changing table, landing on his head
- This reportedly happened 2 days ago
- He is brought to care today because his scalps is “boggy, like a rotten tomato”

Skull Fracture

- A skull x-ray shows “2 parallel linear non-depressed fractures of the right and left parietal bones”

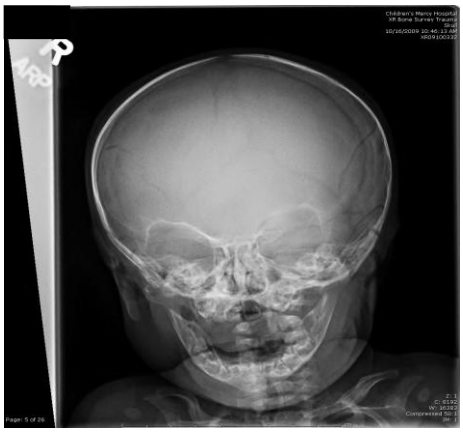

Skull Fractures

- Where on the head is the parietal bone?

1) Very top
2) Back
3) Sides
4) Front
5) None of the above

MIC: skull fractures

Skull Fractures

- The fact that the parents brought the child in 2 days after the reported trauma is

1) Not indicative of abuse
2) A worrisome delay in seeking care
3) None of the above

MIC: Scalp and Head Bruises

Skull Fractures

- The two parallel skull fracture are

1) Possible after one episode of trauma
2) Indicative of two episodes of trauma
3) Indicate abuse
4) 2 and 3

MIC: Bending Fractures

Abdominal Trauma

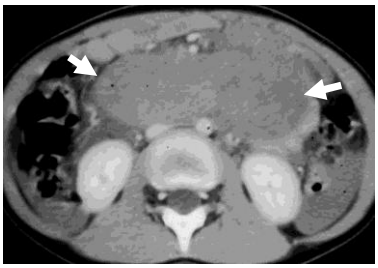

Abdominal Trauma Case

- A 2 yo is brought to the hospital for abdominal pain
- There is no history of trauma
- An x-ray shows “bowel wall edema”
- A CT shows a “grade 2 liver laceration”

Abdominal Trauma Case

- Why are the x-ray and CT results different?

1) The radiologist must have made a mistake
2) X-rays are generally not done on the abdomen
3) X-rays are poor at detecting some types of abdominal injury
4) 1 and 3
5) 2 and 3

MIC: Abdominal Injury, Radiology Studies

Injury History

- A 3 month old is brought to the hospital for concern that something is wrong with his arm.
- He reportedly fell off of a couch earlier this morning
- His x-ray shows the following

Transverse Fracture

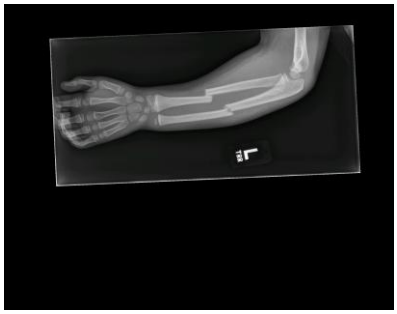

Injury History

- Falling off of a couch is

1) A possible explanation for the injury
2) Not a possible explanation for the injury

MIC: Injury history mechanism

MIC: Development

MIC: Injury history checklist

Final “Take Home Points”

- Information from the scene investigation often changes the medical diagnosis in cases of suspected child abuse
- Medical-investigative collaboration is critical!
- The more you know and understand, the higher the quality of the collaboration